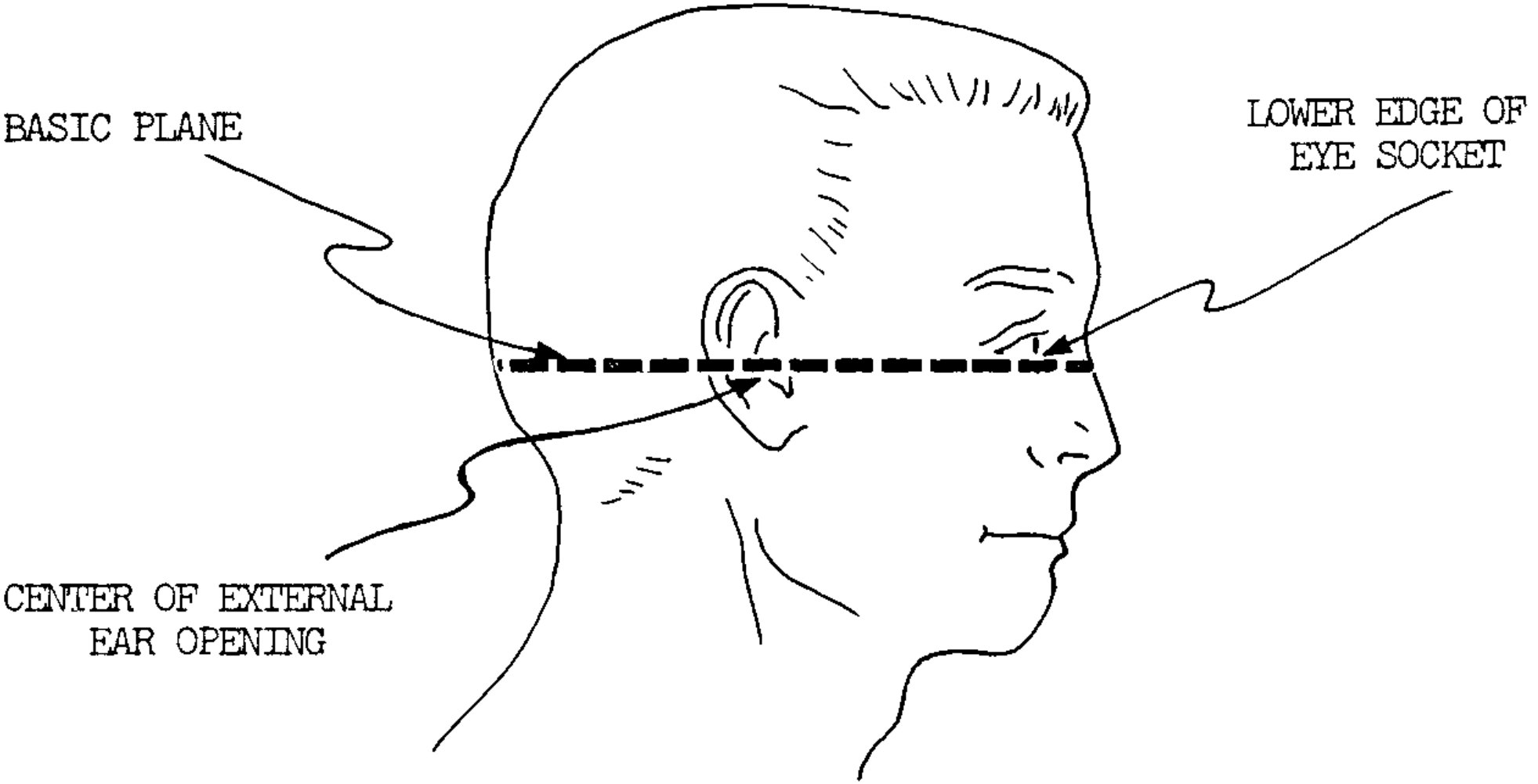
BASIC PLANE
LOWER EDGE OF
EYE SOCKET
CENTER OF EXTERNAL
EAR OPENING

Figure 1